



Thoracic Ultrasonography for the Pulmonary Specialist

Seth J. Koenig, MD; Mangala Narasimhan, DO, FCCP; and Paul H. Mayo, MD, FCCP

Thoracic ultrasonography is a noninvasive and readily available imaging modality that has important applications in pulmonary medicine outside of the ICU. It allows the clinician to diagnose a variety of thoracic disorders at the point of care. Ultrasonography is useful in imaging lung consolidation, pleural-based masses and effusions, pneumothorax, and diaphragmatic dysfunction. It can identify complex or loculated effusions and be useful in planning treatment. Identifying intrathoracic mass lesions can guide sampling by aspiration and biopsy. This article summarizes thoracic ultrasonography applications for the pulmonary specialist, related procedural codes, and reimbursement. The major concepts are illustrated with cases. These case summaries are enhanced with online supplemental videos and chest radiograph, chest CT scan, and ultrasound correlation.

CHEST 2011; 140(5):1332–1341

Editor's Note: The online version of this article includes three videos intended to enhance the major concepts presented. The videos can be viewed at: <http://chestjournal.chestpubs.org/content/140/5/1332.full>

Thoracic ultrasonography is a noninvasive and readily available imaging modality that has important applications in pulmonary medicine. Thoracic ultrasonography gives the clinician a powerful tool that enables the pulmonary consultant to diagnose a variety of thoracic disorders quickly at the point of care. This article summarizes applications of thoracic ultrasonography for the pulmonary specialist. The article is accompanied by online videos that are designed to enhance the reader's understanding of the field. For the purposes of this article, thoracic ultrasonography refers to imaging of the chest wall, pleural space, diaphragms, and the lungs. The article is designed specifically for the pulmonary specialist and, therefore, does not consider ultrasonographic assessment of the heart and its great vessels.

Manuscript received February 10, 2011; revision accepted June 23, 2011.

Affiliations: From the Department of Medicine, Long Island Jewish Medical Center, New Hyde Park, NY.

Correspondence to: Seth J. Koenig, MD, Department of Medicine, Long Island Jewish Medical Center, 270-05 76th Ave, New Hyde Park, NY 11040; e-mail: skoenig@nshs.edu

© 2011 American College of Chest Physicians. Reproduction of this article is prohibited without written permission from the American College of Chest Physicians (<http://www.chestpubs.org/site/misc/reprints.xhtml>).

DOI: 10.1378/chest.11-0348

The usefulness of thoracic ultrasonography rests with its immediate application. This requires a paradigm shift in the approach to thoracic imaging. The ultrasound examination is integrated with the results of the physical examination and the clinical impression. Observation, palpation, percussion, and auscultation are key elements in the evaluation of any patient. The ultrasound examination of the chest extends the physical examination and allows the examiner to better characterize disease processes. Thoracic ultrasonography is performed at the bedside of the patient by the pulmonary consultant who is aware of all aspects of the clinical situation. There is no time delay, which is inherent to standard radiographic techniques, and the pulmonary consultant applies the results with full clinical knowledge of the patient, unlike the radiologist. Chest radiography and chest CT scan are important imaging modalities for the pulmonary consultant and should be used in conjunction with ultrasound to make treatment decisions.

EQUIPMENT REQUIREMENTS

Most modern portable ultrasound machines are capable of all aspects of thoracic imaging. A phased array transducer (frequency range 3.5–5.0 MHz) with a small footprint designed for cardiac imaging can be used for most aspects of the thoracic examination. This transducer type offers adequate penetration and resolution of deep structures in the thorax. For

detailed examination of the pleural surface and adjacent chest wall the examiner will need to use a high-frequency linear vascular transducer (frequency range 7.5-10.0 MHz) in order to optimize the resolution of near field structures. Use of a high-frequency probe improves resolution but sacrifices depth of penetration. Therefore, high-frequency probes are not suitable for examination of deeper thoracic structures, such as atelectatic lung within a large pleural effusion, the entire curvature of the diaphragm, or lung consolidation that is beyond the depth of penetration of a typical vascular probe. Doppler capability is not a requirement for comprehensive thoracic ultrasonography.

HOW TO PERFORM THORACIC ULTRASONOGRAPHY

Thoracic ultrasonography is best performed with the patient in the seated position. By convention, the transducer is held in longitudinal scanning plane with the transducer indicator in a cephalad position. With standard machine setup, this means that images on the left side of the screen are cephalad structures. Knowledge of machine control is integral to image acquisition. Total, near, and far field gain must be adjusted for optimal image quality. Depth should be set to place the target structure in the middle of the screen and/or focal point should be adjusted for optimal image quality.

The transducer is applied with firm pressure perpendicular to the chest wall over a rib interspace. Adjacent interspaces are examined by sliding the transducer to the next interspace. In this way, the examiner lays down a scan line as the transducer is moved over the chest wall. Scan lines should be performed with an orderly series of longitudinal movements of the transducer. Multiple adjacent scan lines are performed such that the entire chest wall is methodically examined at multiple interspaces (Fig 1). The examiner develops a three-dimensional model of the thorax by performing multiple two-dimensional tomographic ultrasound planes. If an abnormality is identified during the course of the scanning, the examiner then focuses on that point.

Bone blocks the transmission of ultrasound, so that when a focal abnormality lies deep to a rib, the transducer may be angled to look over or under the rib. Aerated lung also blocks transmission of ultrasound, so the liver and spleen may be used as ultrasound windows by angling the transducer such that the scanning plane passes through the liver or spleen to image the lung. Consolidated lung and pleural effusion transmit ultrasound very well, and may offer a window for examination of the mediastinum and the lung (Fig 2, Video 1).

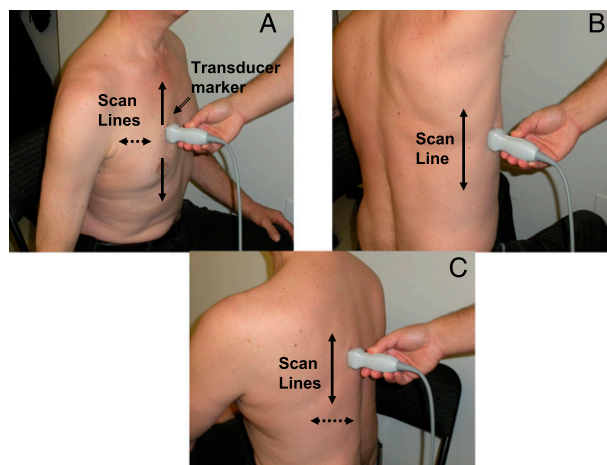


FIGURE 1. Ultrasonograph scan lines. A, Anterior scan line. The ultrasound probe is held firmly perpendicular to chest wall. The ultrasonographer moves the ultrasound probe cephalad and caudad in one longitudinal line and then moves either lateral or medial and repeats a longitudinal scan. Transducer marker points cephalad. B, Midaxillary scan line. C, Posterior scan line. (The patient provided written consent for the use of this photograph.)

LUNG ULTRASONOGRAPHY

Lung ultrasonography may be integrated into bedside evaluation as a valuable adjunct to the standard chest radiograph and CT scan and, as an extension conceptually, to physical examination of the thorax. It is paired with ultrasonographic evaluation of the pleural space, but it also has usefulness independent of pleural pathology. This section will review applications of lung ultrasonography that are of interest to the pulmonary consultant.

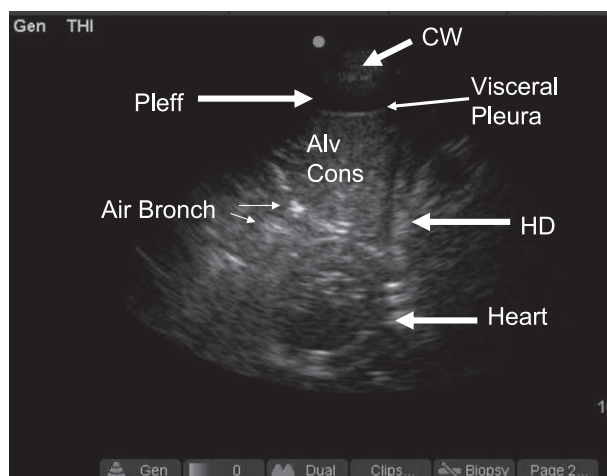


FIGURE 2. Alveolar consolidation as ultrasound window to mediastinal structures. Longitudinal view midaxillary line on left. Air Bronch = air bronchogram; Alv Cons = alveolar consolidation; CW = chest wall; HD = hemidiaphragm; Pleff = pleural effusion.

Key Findings

The standard semiology of lung ultrasonography was developed by Dr Daniel Lichtenstein in the 1990s. His original work defined all the important findings of lung ultrasonography¹ and has been fully validated by subsequent investigators. For purposes of efficient reporting, we suggest that his nomenclature be standard in the field.

When performing lung ultrasonography, the examiner positions the transducer over an interspace such that the rib shadows are located on either side of the screen (Fig 3, Video 2). The pleural line is identified approximately 5 mm deep to the rib cortex. The pleural line, which appears as a shimmering echogenic linear structure, is examined for movement. This may occur either with the respiratory or cardiac cycle and represents movement of the visceral pleura against the parietal pleura. This movement is called lung sliding when resulting from respiratory movement of the lung, and lung pulse when it results from cardiac movement.^{2,3} Reducing gain and depth improve visualization of the pleural line. The presence of lung sliding or lung pulse at the pleural interface is absolute evidence that there is no pneumothorax at the site of the examination. Multiple sites may be examined quickly to definitively rule out pneumothorax. The absence of lung sliding suggests pneumothorax, but there are a variety of other possibilities that must be considered, such as pleurodesis. We routinely assess for lung sliding before and after any transthoracic intervention. Provided lung sliding was present before the procedure, loss of lung sliding following the procedure is strong evidence for iatrogenic pneumothorax. The presence of a lung point, defined as intermittent visualization of lung sliding from mobile partially collapsed lung, is diagnostic for pneumothorax⁴ (Video 3).

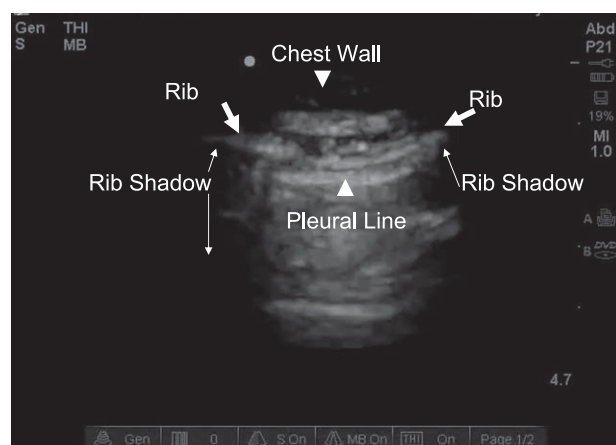


FIGURE 3. Normal pleural line. Longitudinal anterior chest ultrasonograph displaying typical anatomic landmarks in normal lung.

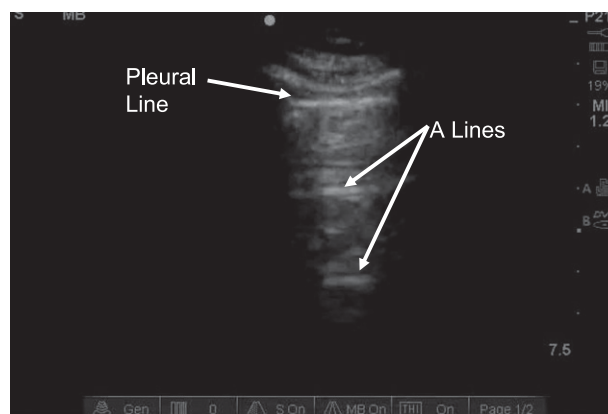


FIGURE 4. Normal aeration pattern with A-lines. Longitudinal scan anterior chest. A-lines are repetitive reverberation artifacts, with equal distances between them and the pleural line.

In order to assess the underlying lung, the examiner must change the machine to a deeper depth setting. Normally aerated lung shows an A-line pattern, which is a reverberation artifact (Fig 4, Video 4). B-lines indicate an abnormality in the interstitial or alveolar compartment.⁵ These comet-tail artifacts project from the pleural line, move with respiration, and extend to the bottom of the ultrasound screen (Fig 5, Video 5). In normal individuals, it is common to find a few B-lines over the lower lateral chest and an occasional single B-line elsewhere. More than three B-lines in a single field is abnormal. Diffuse B-line pattern may result from cardiogenic pulmonary edema and is associated with a smooth pleural line. When B-lines result from noncardiogenic lung injury, such as ARDS, interstitial lung disease, or pneumonia, the pleural surface is often irregular, and B-line distribution is nonhomogeneous with small subpleural areas of lung consolidation.^{6,7} Lung disease may be focal or diffuse, so that the cardinal findings on ultrasonography of the lung may be multifocal or unifocal, similar to distribution of disease found on standard chest radiography. The presence of an A-line pattern over the anterior chest, whether unilateral or bilateral, rules out cardiogenic pulmonary edema, as the presence of A-line pattern indicates that the pulmonary artery occlusion pressure is < 18 mm Hg.⁸

Consolidated lung is tissue density and has similar echogenicity as the liver and spleen⁹ (Fig 6, Video 6). Sonographic air bronchograms are visualized as punctate echogenic foci within consolidated lung. If they move in synchrony with the respiratory cycle, the bronchus supplying the area is patent¹⁰ (Video 7). Small areas of subpleural consolidation with irregularity of the pleural line occur with disease of the peripheral lung.

Tumor masses adjacent to the pleural surface are readily detected with lung ultrasonography.¹¹ The

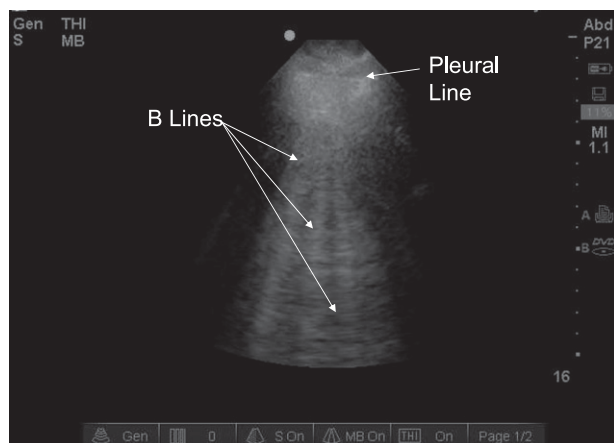


FIGURE 5. B-lines. Longitudinal scan anterior chest. B-lines must efface A-lines and project to bottom of screen.

tumor mass is generally hypoechoic and surrounded by aerated lung. (Fig 7, Video 8). A small mass may require the examiner to angle the probe over or under the rib for optimal visualization. Pleural and chest wall invasion by tumor is discernible with ultrasonography and requires use of a high-frequency vascular probe. Ultrasonography is more accurate than chest CT scan for detection of chest wall invasion.¹² A mass within consolidated lung may also be visible, as is a lung abscess. Typical features of a peripheral abscess reveal irregular hyperechoic borders abutting the pleural surface at an acute angle. Internally, the abscess cavity will be heterogeneous with relatively anechoic areas with echogenic foci, corresponding to both air and tissue necrosis (Fig 8, Video 9).

Pleural fluid causes compressive atelectasis of the adjacent lung. The degree of atelectasis is proportional to the size of the effusion and yields an

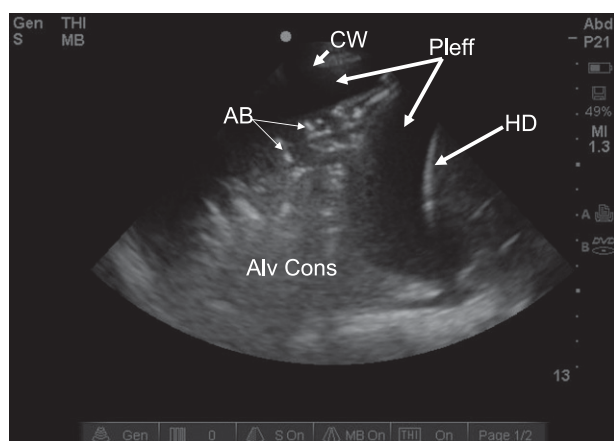


FIGURE 6. Alveolar consolidation with pleural effusion. Longitudinal scan midaxillary on right. Notice ultrasonographic hepatization of airless lung with punctate areas of white representing air bronchograms. AB = air bronchogram. See Figure 2 legend for expansion of other abbreviations.

ultrasonographic pattern of alveolar consolidation. In large effusions, the compressed airless lung floats with dynamic movement within the effusion. At the interface between atelectatic lung and aerated lung, there is often an echogenic boundary from which comet-tail artifacts arise. These have the appearance of B-lines, but are not so named, as strictly speaking, B-lines originate at the pleural surface (Fig 9, Video 10).

Clinical Applications

Lung ultrasonography may be used as a diagnostic modality. The scan is performed in order to establish and follow the course of disease. The clinician uses the ultrasound findings to supplement chest radiography and CT scan. The hand-held ultrasound machine provides a convenient, portable, and reliable means of identifying a variety of disease processes without the delay and radiation associated with standard radiographic techniques. Lung ultrasonography is superior to physical examination and has similar performance characteristics as chest radiography and CT scan for a variety of lung diseases.^{13,14} Ultrasound can be used in algorithmic fashion for the bedside evaluation of respiratory failure.¹⁵ Another major advantage of lung ultrasonography is that it may reduce patient exposure to ionizing radiation. The overuse of CT scanning raises the concern of inappropriate patient exposure to radiation.¹⁶ It is possible to replace CT scanning with thoracic ultrasonography for certain applications. Lung ultrasonography has limitations. Lung lesions that are surrounded by aerated lung are not visible with ultrasonography, such as a pulmonary nodule or mass and most mediastinal structures.

PLEURAL ULTRASONOGRAPHY

Pleural ultrasonography is an easy-to-use modality that aids in the identification and characterization of pleural abnormalities. It can also be used to guide pleural procedures. Equipment requirements and scanning tactics are identical to those used for lung ultrasonography as described previously.

Key Findings

Pleural fluid appears as an anechoic or hypoechoic space within the thorax. An anechoic space is black, whereas a hypoechoic effusion has reduced echogenicity relative to tissue density, using the liver as a reference standard. Free-flowing pleural fluid distributes in a dependent manner. In the seated patient, pleural fluid is found in the lower thorax, whereas in the supine patient it is found in posterior location.

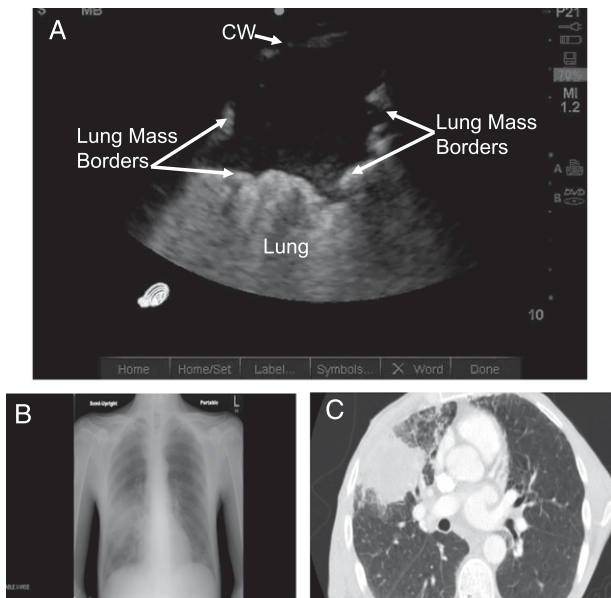


FIGURE 7. Lung mass. A, Ultrasonograph image of lung mass. Longitudinal scan, anterior right chest. Notice irregular borders with hypoechoic interior. B, Chest radiograph. C, Chest CT scan. Transthoracic biopsy proved non-small cell adenocarcinoma. See Figure 2 for expansion of abbreviation.

Loculated pleural effusions may occur any place in the thorax and require targeted ultrasound scanning.

The typical boundaries that subtend a pleural effusion are the chest wall, the hemidiaphragm, and the visceral pleural surface. Identification of the hemidiaphragm requires visualization of the liver or spleen in order to avoid inadvertent subdiaphragmatic device insertion. Identification of the visceral pleural surface is critical in order to avoid inadvertent pleural laceration.

There are typical dynamic findings associated with pleural effusions. These include diaphragmatic move-

ment, movement of the atelectatic lung within the pleural effusion, and movement of tissue elements within the pleural effusion. These result from the effect of respiratory and cardiac function.

Ultrasonography allows characterization of the size of a pleural effusion. The size of a pleural effusion may be estimated qualitatively as small, moderate, or large. A quantitative approach requires several measurements from frozen images and correlates with the amount of pleural fluid removed with thoracentesis.¹⁷ The authors do not do this in ordinary clinical operations.

Ultrasonography is superior to standard radiography and chest CT scan to characterize the internal complexity of an effusion, such as septations¹⁸ (Figs 10, 11, Videos 11, 12). The presence of pleural fluid complexity suggests an exudative effusion, but an anechoic effusion may be either transudative or exudative.¹⁹⁻²² Pleural ultrasonography findings may suggest specific diagnoses. For instance, a malignant pleural effusion may have metastatic foci on the hemidiaphragm (Fig 12, Video 13).

Pitfalls

Most pleural effusions are readily identified using ultrasonography. However, obesity, heavy musculature, and soft tissue edema may degrade image quality such that the examiner is unable to clearly identify the inside of the chest wall or the visceral pleural surface. The pleural effusion may be so echogenic that it is not identifiable with confidence. This occurs with complicated pleural effusion, empyema, hemothorax, hydrofibrothorax, fibropurulent collection, and coexisting consolidation. These situations require expert-level pleural ultrasonography.

ULTRASONOGRAPHY FOR PROCEDURAL GUIDANCE

Thoracentesis

Ultrasonography allows the pulmonary consultant to perform thoracentesis in a safe and efficient manner. Ultrasonography reduces complications, such as pneumothorax, and increases success of fluid retrieval when compared with traditional methods of guidance.^{23,24}

The examiner should seek unequivocal identification of a pleural effusion. The assignment is simple: identification of the best site, angle, and depth for needle insertion that avoids injury to organs that may be adjacent to the pleural effusion. The ultrasound image should be obtained with the patient in the position in which the procedure will be performed. Any significant deviation in position will shift the pleural fluid and may cause unintended complications. The transducer angle and position on the chest wall that identifies a safe site for thoracentesis should

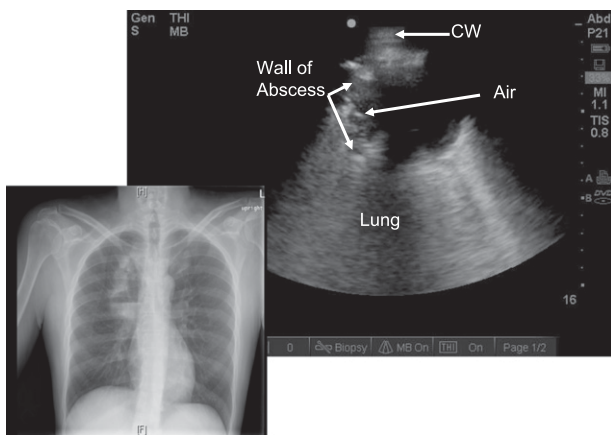


FIGURE 8. Lung abscess. Longitudinal scan posterior superior chest. Notice irregular borders with small amount of air in periphery. Center is hypoechoic consistent with fluid or necrotic tissue. Air = air within the cavity. See Figure 2 legend for expansion of other abbreviation.

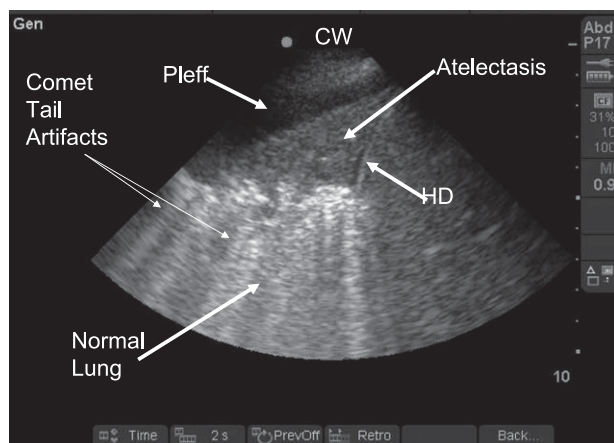


FIGURE 9. Small pleural effusion with atelectasis and comet-tail artifact. Longitudinal scan midaxillary line on right. There is a small pleural effusion with atelectatic lung. Comet-tail artifacts appear at interface of normal aerated lung and atelectatic lung. See Figure 2 legend for expansion of abbreviations.

be replicated when inserting the needle. Depth of needle insertion may be measured from the ultrasound image. Significant chest wall edema or obesity may result in underestimation of the distance required to access the fluid, as pressing firmly with the transducer may cause significant compression artifact that may result in an underestimate of depth required for needle insertion.²⁵ Some operators interrogate the intercostal space prior to needle insertion in order to identify an aberrantly positioned intercostal vessel that precludes needle insertion at that site. Although there are no published data to support this, it may be a reasonable precaution to avoid the rare complication of vascular injury.

Lung sliding should be assessed before and following thoracentesis. The loss of lung sliding following thoracentesis when it was present before the procedure indicates that there has been a procedure-related

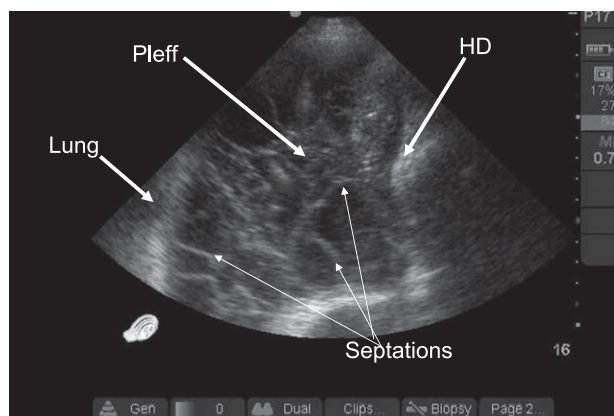


FIGURE 10. Complex septated pleural effusion. Longitudinal scan midaxillary line left side. Notice the weblike appearance of septations. This proved resistant to standard catheter drainage. See Figure 2 legend for expansion of abbreviations.

pneumothorax. The finding of lung sliding following thoracentesis obviates the need for chest radiography performed in order to rule out pneumothorax.

Ultrasonography aids in selection of a safe insertion site for a needle into a pleural effusion. The pulmonary consultant may elect to do a simple thoracentesis for diagnostic or therapeutic purposes. Access to the pleural effusion is followed by wire insertion that allows a variety of pleural drainage devices to be inserted, such as small-bore drainage catheters, large-bore chest tubes, long-term tunneled drainage catheters, and large introducers for medical thoracoscopy. In addition to its role in selecting a safe trajectory for device insertion, ultrasonography may be useful in making management decisions related to pleural intervention. For example, a free-flowing, anechoic, nonseptated effusion may be best managed with simple thoracentesis, whereas an echodense, septated effusion may require drainage with a larger catheter. If the septations are thick walled and immobile, the clinician may, in the appropriate clinical context, proceed to surgical intervention. In managing the complicated pleural space, the standard chest radiograph is a suboptimal imaging modality, so serial chest CT scans are a usual concomitant in the management of complicated pleural effusions. The pulmonary consultant may substitute serial pleural ultrasonography as an alternative, thereby reducing radiation exposure. Ultrasonography may be used to check wire and/or device position during pleural intervention. Multiple loculations may require more than one drainage catheter targeted by ultrasonography.

Transthoracic Aspiration/Biopsy

Ultrasonography can be used to identify pleural and lung lesions that are adjacent to the chest wall. This allows the pulmonary consultant to aspirate and perform biopsy of the lesions with a transthoracic approach. When standard radiography or CT scanning identifies a lesion, the pulmonary consultant can determine the need for biopsy. Ultrasonographic-guided biopsy can be performed safely with high sensitivity for diagnosis using needle aspiration or a cutting biopsy needle.¹¹ If the lesion can be identified with ultrasonography, the best site, angle, and depth are determined for device insertion. In our experience, it is not necessary to use real-time ultrasound guidance for needle insertion for transthoracic procedures.²⁶ The examiner can assess the size, the degree of respiratory movement, and the vascularity (if color Doppler is available) of the lesion. We routinely assess the pleural surface for lung sliding before and after the biopsy to rule out a pneumothorax.

Microbiologic diagnosis or therapeutic drainage of a pleural-based lung abscess may be guided with

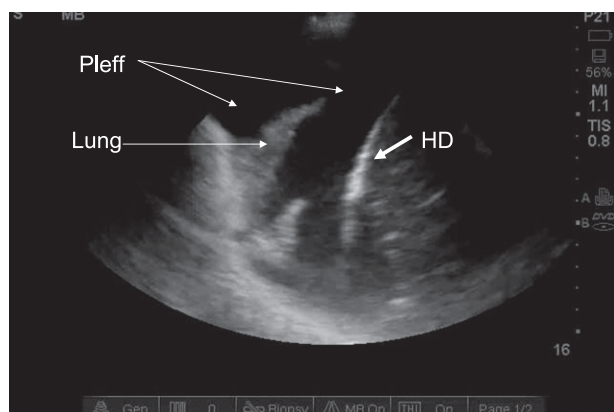


FIGURE 11. Simple anechoic pleural effusion. Longitudinal scan midaxillary line on left. Notice anechoic appearance of pleural effusion with atelectatic lung floating within it. See Figure 2 legend for expansion of abbreviations.

ultrasonography.²⁷ A concern of the procedure is the possibility of soiling the pleural space. This risk is reduced if there is pleural symphysis as detected by loss of lung sliding at the site of needle insertion into the abscess cavity (Video 14).

Assessment of Diaphragmatic Function

Ultrasonography may be used by the pulmonary consultant to assess diaphragmatic function.^{28,29} Compared with fluoroscopy, ultrasonography is more accurate, with the advantage that it can be performed at point of care. The same transducer used for lung ultrasonography identifies the hemidiaphragm in the longitudinal scanning plane at the midaxillary line. Typically, the patient is studied in semisupine position. When assessing diaphragmatic function in patients receiving mechanical ventilatory support, a ventilator-cycled breath will cause the diaphragm to be pushed

in a caudad direction, thereby giving the false impression of normal diaphragmatic contractile function. Therefore, when testing diaphragmatic function the ventilator must be turned to the lowest support setting to avoid a false-negative result. Aerated lung may make it difficult to visualize the hemidiaphragm, particularly on the left. The examiner may angle the ultrasound beam through the liver or spleen to image the diaphragm in its entirety. The diaphragm appears as a thin, curvilinear, echogenic respirophasic structure that normally moves in caudad direction with inspiration (Fig 13, Video 15). Hemidiaphragmatic paralysis is inferred by absent or paradoxical movement of the hemidiaphragm, whereas paresis shows reduced movement during inspiration (Video 16). Deep inspiration, tidal breathing, and sniff testing may be used to demonstrate abnormal diaphragmatic motion. Diaphragmatic movement may be quantified using two-dimensional and M-mode ultrasonography; however, we find qualitative visual assessment is sufficient.

PRACTICAL USE OF BEDSIDE ULTRASONOGRAPHY: A CASE EXAMPLE

A common cause for pulmonary consultation is evaluation of dyspnea. We were called to evaluate a patient with sickle cell disease who presented in the ED with hypoxemia, fever, purulent sputum, and pleuritic chest pain over the lower posterior left thorax. The chest radiograph was clear (Fig 14). The admitting team had ordered a chest CT scan to rule out pulmonary embolism. Thoracic ultrasonography was performed and showed generalized A-line pattern including the anterior chest and a focal area of alveolar consolidation in the posterior segment of the left lower lobe (Videos 17, 18). The generalized A-line pattern ruled out an alveolar interstitial syndrome and, in particular, cardiogenic pulmonary edema. The finding of focal alveolar consolidation with the patient's constellation of symptoms defined presentation with acute chest syndrome. Pneumonia was also in the differential diagnosis, as well as focal atelectasis. We canceled the chest CT scan and recommended treatment of acute chest syndrome. The repeat chest radiography performed the following day showed a left lower lobe consolidation. Review of the patient record showed that he had been subjected to seven chest CT scans for similar presentation within the past 3 years.

LIMITATIONS OF THORACIC ULTRASONOGRAPHY

Limitations of image quality of thoracic ultrasonography are obesity, heavy musculature, edema, and an inability to properly position a patient for a complete

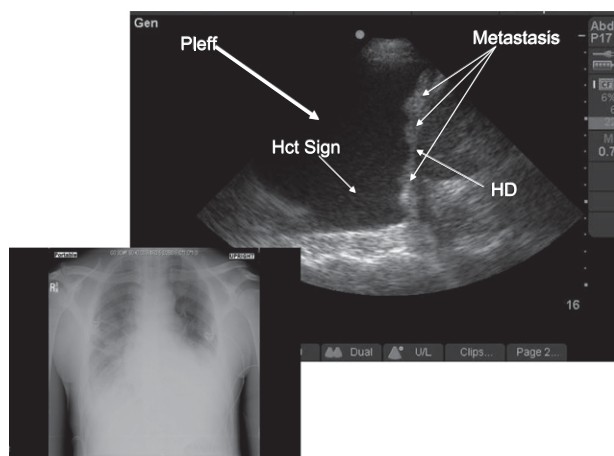


FIGURE 12. Large pleural effusion with evidence of diaphragmatic pleural metastasis. Longitudinal scan midaxillary on left. Patient had renal cell carcinoma. Hct sign = hematocrit sign. See Figure 2 legend for expansion of other abbreviations.

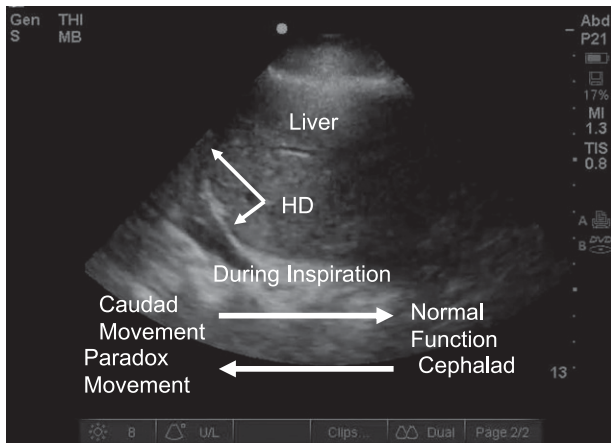


FIGURE 13. Frozen image of diaphragm with arrows indicating caudal and cephalad direction. With normal diaphragmatic function, there is caudal movement during inspiration. Cephalad movement during inspiration indicates paradoxical motion. Refer to video 15. See Figure 2 legend for expansion of abbreviation.

examination. However, even with these limitations, an experienced examiner can generally obtain important information. The rate of incomplete, ambiguous, or noninterpretable studies depends on the examiner and the population being examined. Another limitation of thoracic ultrasonography is the difficulty in documentation of the imaging component of the examination results. Full image documentation of lung ultrasonography entails capturing, in digital format, multiple scan lines that are impractical to review for serial comparison and difficult to label and store. Most operators will capture a few representative images either as video clips or as printed single images, while writing a brief written report. It is, therefore, difficult to do visual comparisons of serial lung ultrasonography examinations.

BARRIERS TO IMPLEMENTATION

Thoracic ultrasonography requires training in image acquisition, image interpretation, and cognitive background that allows integration of the results into the clinical management of the patient, as the pulmonary consultant assumes all responsibility for the performance and interpretation of the study. Thoracic ultrasonography requires specific training in image acquisition, image interpretation, and in the cognitive elements of the field.

CHARGES, CODING, AND REIMBURSEMENT

There are routine charges, defined as a global fee, a technical fee, and a professional fee, where the global fee is the combined sum of the technical and professional charges. If thoracic ultrasonography is performed in the hospital setting, all of the technical costs are absorbed by the institution, as the hospital owns the machine and provides the supplies required for scanning. The clinician receives payment only for the professional component of the procedure. In contrast, office-based thoracic ultrasonography allows reimbursement for both the technical and professional component, provided the pulmonary practice owns the ultrasound machine. The current procedural terminology codes that are relevant to thoracic ultrasonography are as follows:

1. **76604** Ultrasound, chest (includes mediastinum), real time with image documentation. When the pulmonary consultant performs thoracic ultrasonography with image documentation and a report of the results placed in the chart, he or

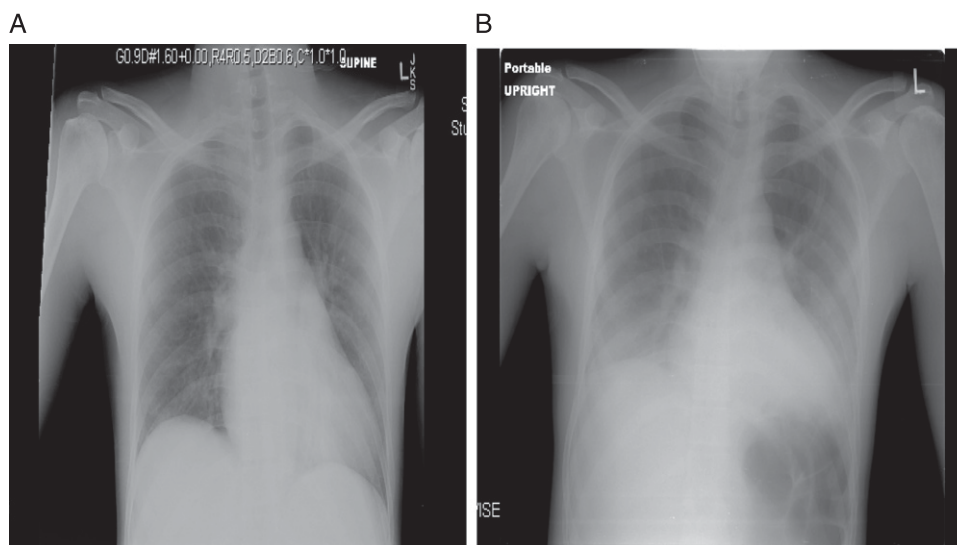


FIGURE 14. Portable chest radiograph of case patient. A, Initial chest radiograph. B, Chest radiograph 12 h later.

she should bill for this activity using this code. Just as a radiologist would submit charge for a chest radiograph, the pulmonary consultant should do the same.

2. **76942** Ultrasonic guidance for needle placement. When the pulmonary consultant uses ultrasonography to guide needle insertion with image documentation and a report, he or she should bill for this code, just as a radiologist would do.
3. **75989** Ultrasonic guidance of percutaneous drainage. This code is appropriate for guidance of drainage devices that will stay in the patient for some period of time (eg, chest tubes, tunneled catheters). Image documentation and a report are required.

A recent generation, portable, fully equipped ultrasound machine with a cardiac and vascular transducer that permits all aspects of ultrasonography including Doppler can be purchased for approximately \$40,000. This level of capability is not required for the pulmonary practice that performs only thoracic ultrasonography. A new machine with a single cardiac transducer without Doppler that has full thoracic capability costs approximately \$20,000. Very capable preowned machines are available for <\$10,000. It is important to purchase the machine with an adequate warranty.

The decision to purchase an office-based machine is predicated on volume of service, insurance mix, and reimbursement levels. In the New York City area, Medicare reimbursement rate is heavily weighted toward global reimbursement. The 76604-26 code (professional component only) pays approximately \$30.00, whereas the global fee (technical plus professional components) pays approximately \$100.00. The 76942-26 (professional) and 76942 (global) pay approximately \$35.00 and \$220.00, respectively. Purchase of a machine for office-based ultrasonography is economically justifiable if the practice is structured to perform thoracic ultrasonography on a regular basis and is particularly feasible if the practice performs office-based thoracentesis. Reimbursement rates vary according to geographic area and insurer, so the reader should consult with their local carrier.

CONCLUSION

Thoracic ultrasonography is a safe, easy-to-learn, portable imaging modality that has usefulness for the pulmonary consultant. The authors routinely take a portable ultrasound machine on hospital rounds when performing pulmonary consultations. The history and physical examination is followed, when indicated, by a goal-directed ultrasound examination.

Diagnostic and therapeutic procedures may be guided with ultrasonography at the point of care, minimizing ionizing radiation. Ultrasound can also be used routinely in the outpatient setting with the ultrasound machine deployed in the examining room on a real-time basis. With continued reduction in both size and cost of ultrasound machines, this imaging modality will find its place at the bedside of patients, both as an extension of the physical examination and to safely guide thoracic procedures.

ACKNOWLEDGMENTS

Financial/nonfinancial disclosures: The authors have reported to *CHEST* that no potential conflicts of interest exist with any companies/organizations whose products or services may be discussed in this article.

Other contributions: This work was performed at Long Island Jewish Medical Center, New Hyde Park, NY.

Additional information: The Videos can be found in the online version of the article at <http://chestjournal.chestpubs.org/content/140/5/1332.full>.

REFERENCES

1. Lichtenstein DA. *Whole Body Ultrasonography in the Critically Ill*. Berlin, Germany: Springer; 2010:117-208.
2. Lichtenstein DA, Menu Y. A bedside ultrasound sign ruling out pneumothorax in the critically ill. Lung sliding. *Chest*. 1995;108(5):1345-1348.
3. Lichtenstein DA, Mezière G, Lascols N, et al. Ultrasound diagnosis of occult pneumothorax. *Crit Care Med*. 2005; 33(6):1231-1238.
4. Lichtenstein D, Mezière G, Biderman P, Gepner A. The "lung point": an ultrasound sign specific to pneumothorax. *Intensive Care Med*. 2000;26(10):1434-1440.
5. Lichtenstein D, Mézière G, Biderman P, Gepner A, Barré O. The comet-tail artifact. An ultrasound sign of alveolar-interstitial syndrome. *Am J Respir Crit Care Med*. 1997;156(5):1640-1646.
6. Copetti R, Soldati G, Copetti P. Chest sonography: a useful tool to differentiate acute cardiogenic pulmonary edema from acute respiratory distress syndrome. *Cardiovasc Ultrasound*. 2008;6:16.
7. Agricola E, Bove T, Oppizzi M, et al. "Ultrasound comet-tail images": a marker of pulmonary edema: a comparative study with wedge pressure and extravascular lung water. *Chest*. 2005;127(5):1690-1695.
8. Lichtenstein DA, Mezière GA, Lagoueyte JF, Biderman P, Goldstein I, Gepner A. A-lines and B-lines: lung ultrasound as a bedside tool for predicting pulmonary artery occlusion pressure in the critically ill. *Chest*. 2009;136(4):1014-1020.
9. Lichtenstein DA, Lascols N, Mezière G, Gepner A. Ultrasound diagnosis of alveolar consolidation in the critically ill. *Intensive Care Med*. 2004;30(2):276-281.
10. Lichtenstein D, Mezière G, Seitz J. The dynamic air bronchogram. A lung ultrasound sign of alveolar consolidation ruling out atelectasis. *Chest*. 2009;135(6):1421-1425.
11. Diacon AH, Theron J, Schubert P, et al. Ultrasound-assisted transthoracic biopsy: fine-needle aspiration or cutting-needle biopsy? *Eur Respir J*. 2007;29(2):357-362.
12. Bandi V, Lunn W, Ernst A, Eberhardt R, Hoffmann H, Herth FJ. Ultrasound vs. CT in detecting chest wall invasion by tumor: a prospective study. *Chest*. 2008;133(4):881-886.
13. Lichtenstein D, Goldstein I, Mourgeon E, Cluzel P, Grenier P, Rouby JJ. Comparative diagnostic performances of

- auscultation, chest radiography, and lung ultrasonography in acute respiratory distress syndrome. *Anesthesiology*. 2004; 100(1):9-15.
14. Zanobetti M, Poggioni C, Pini R. Can chest ultrasonography substitute standard chest radiography for evaluation of acute dyspnea in the emergency department? *Chest*. 2011; 139(5):1140-1147.
 15. Lichtenstein DA, Mezière GA. Relevance of lung ultrasound in the diagnosis of acute respiratory failure: the BLUE protocol. *Chest*. 2008;134(1):117-125.
 16. Brenner DJ, Hall EJ. Computed tomography—an increasing source of radiation exposure. *N Engl J Med*. 2007; 357(22):2277-2284.
 17. Vignon P, Chastagner C, Berkane V, et al. Quantitative assessment of pleural effusion in critically ill patients by means of ultrasonography. *Crit Care Med*. 2005;33(8):1757-1763.
 18. McLoud TC, Flower CD. Imaging the pleura: sonography, CT, and MR imaging. *AJR Am J Roentgenol*. 1991;156(6): 1145-1153.
 19. Chen HJ, Tu CY, Ling SJ, et al. Sonographic appearances in transudative pleural effusions: not always an anechoic pattern. *Ultrasound Med Biol*. 2008;34(3):362-369.
 20. Chian CF, Su WL, Soh LH, Yan HC, Perng WC, Wu CP. Echogenic swirling pattern as a predictor of malignant pleural effusions in patients with malignancies. *Chest*. 2004; 126(1):129-134.
 21. Yang PC, Luh KT, Chang DB, Wu HD, Yu CJ, Kuo SH. Value of sonography in determining the nature of pleural effusion: analysis of 320 cases. *AJR Am J Roentgenol*. 1992;159(1):29-33.
 22. Tu CY, Hsu WH, Hsia TC, et al. Pleural effusions in febrile medical ICU patients: chest ultrasound study. *Chest*. 2004; 126(4):1274-1280.
 23. Gordon CE, Feller-Kopman D, Balk EM, Smetana GW. Pneumothorax following thoracentesis: a systematic review and meta-analysis. *Arch Intern Med*. 2010;170(4):332-339.
 24. Diacon AH, Brutsche MH, Soler M. Accuracy of pleural puncture sites: a prospective comparison of clinical examination with ultrasound. *Chest*. 2003;123(2):436-441.
 25. Mayo PH, Doelken P. Pleural ultrasonography. *Clin Chest Med*. 2006;27(2):215-227.
 26. Yang PC. Ultrasound-guided transthoracic biopsy of the chest. *Radiol Clin North Am*. 2000;38(2):323-343.
 27. Yang PC, Luh KT, Lee YC, et al. Lung abscesses: US examination and US-guided transthoracic aspiration. *Radiology*. 1991;180(1):171-175.
 28. Gerscovich EO, Cronan M, McGahan JP, Jain K, Jones CD, McDonald C. Ultrasonographic evaluation of diaphragmatic motion. *J Ultrasound Med*. 2001;20(6):597-604.
 29. Patel AS, O'Donnell C, Parker MJ, Roberts DH. Diaphragm paralysis definitively diagnosed by ultrasonography and postural dependence of dynamic lung volumes after seven decades of dysfunction. *Lung*. 2007;185(1):15-20.